Penetrating Abdominal Trauma

Section I: Scenario Demographics

Scenario Title:	Penetrating Abdominal Trauma
Date of Development:	08/10/2022
Target Learning Group:	Juniors (PGY 1 – 2) Seniors (PGY ≥ 3) All Groups

Section II: Scenario Developers

Scenario Developer(s):	Dr. Lily Edelson
Affiliations/Institution(s):	University of British Columbia, St. Paul's Hospital
Contact E-mail (optional):	Lily.edelson@alumni.ubc.ca

Section III: Curriculum Integration

Learning Goals & Objectives	
Educational Goal:	1. Decision to intubate prior to CT scan in a patient who could become unstable 2. Bedside US to diagnose patient in shock 3. Proper primary and secondary survey to identify wounds 4. Management of the agitated trauma patient
CRM Objectives:	CRM: 1. Recognize an unstable patient with a penetrating trauma requiring airway management prior to imaging 2. Good primary and secondary survey 3. Management of a penetrating abdominal and retroperitoneal wound 4. Shared mental model
Medical Objectives:	Identification of an unstable patient – Shock Index When to intubate prior to imaging Airway management Management and recognition of a penetrating trauma

© 2015 EMSIMCASES.COM
This work is licensed under a Creative Commons Attribution-ShareAlike 4.0 International License.

Case Summary: Brief Summary of Case Progression and Major Events

26-year-old man brought in via bystanders after being found down outside of the ED. He has a penetrating wound to the abdominal left upper quadrant and the left flank. Free fluid is not initially seen on US. Has a shock index >1 at arrival. He has an altered LOC, is agitated, tachycardic, and requires imaging to determine extent of his injuries. He requires airway management prior to CT scan. If airway is not controlled he will arrest in the CT scanner. He also requires management of his penetrating trauma. If the penetrating trauma and shock is not identified and treated he will have a PEA arrest.

References

Tintinalli J.E., & Stapczynski J, & Ma O, & Yealy D.M., & Meckler G.D., & Cline D.M.(Eds.),Eds. Judith E. Tintinalli, et al. McGraw Hill, 2016, https://accessmedicine.mhmedical.com/content.aspx?bookid=1658&sectionid=109381281.

"Retroperitoneal haemorrhage." *Life in the Fast Lane*, September 3, 2015, https://litfl.com/retroperitoneal-haemorrhage/. Accessed October 30th, 2022.

"Ep 118 Trauma – The First and Last 15 Minutes Part 1." *EM Cases*, December 2018, https://emergencymedicinecases.com/trauma-first-last-15-minutes-part-1/. Accessed October 30th, 2022.

"EM Quick Hits 2 Organophosphate Poisoning, TXA for Hemoptysis, Metacarpal Fracture Rotation, Abdominal Stab Wounds, Pediatric IV Cannulation." *EM Cases*, February 12, 2019, https://emergencymedicinecases.com/em-quick-hits-february-2019/. Accessed November 10th, 2022.

Section IV: Scenario Script

A. Clinical Vignette: To Read Aloud at Beginning of Case

You are notified by your nursing staff that a 26-year-old man has been brought into the trauma bay after being found down outside of the Emergency Department. His clothes are bloody and he is agitated. They are currently getting monitors on him and a set of vital signs. They have been unsuccessful at getting an IV as the patient is agitated. The trauma nurse is asking you to come and assess him.

© 2015 EMSIMCASES.COM
This work is licensed under a Creative Commons Attribution-ShareAlike 4.0 International License.

Penetrating Abdominal Trauma

B. Scenario Cast & Realism

Patient:	Computerized Mannequin	Realism: *Select most important dimension(s)*	Conceptual
	Mannequin		Physical
	Standardized Patient		Emotional/Experiential
	Hybrid		Other:
	Task Trainer		N/A

Confederates	Brief Description of Role

C. Required Monitors

EKG Leads/Wires	Temperature Probe	Central Venous Line
NIBP Cuff	Defibrillator Pads	Capnography
Pulse Oximeter	Arterial Line	Other:

D. Required Equipment

Gloves	Nasal Prongs	Scalpel
Stethoscope	Venturi Mask	Tube Thoracostomy Kit
Defibrillator	Non-Rebreather Mask	Cricothyroidotomy Kit
IV Bags/Lines	Bag Valve Mask	Thoracotomy Kit
IV Push Medications	Laryngoscope	Central Line Kit
PO Tabs	Video Assisted Laryngoscope	Arterial Line Kit
Blood Products	ET Tubes	Other:
Intraosseous Set-up	LMA	Other:

E. Moulage

F. Approximate Timing

Set-Up:	min	Scenario:	min	Debriefing:	min

© 2015 EMSIMCASES.COM
This work is licensed under a Creative Commons Attribution-ShareAlike 4.0 International License.

Penetrating Abdominal Trauma

Section V: Patient Data and Baseline State

A. Patient Profile and History			
Patient Name: John Doe	Age: 26	Weight: 70kg	
Gender: Male	Code Status: assumed C2-Full Code		
Chief Complaint: agitated, tachycardic, found down			
History of Presenting Illness: 26-year-old man found down outside of the Emergency Department. Unknown history, yelling out and is confused and cannot tell you what happened. He has blood on his clothes. You are able to access his chart/medications via his Driver's License that is found in his wallet if looked for			
Past Medical History:	Previous ED visits for drug intoxication - methamphetamines	Medications:	None
Allergies: None			
Social History: known drug user, non-IV			
Family History: Unknown			
Review of Systems:	CNS:	Unknown	
	HEENT:	Unknown	
	CVS:	Unknown	
	RESP:	Unknown	
	GI:	Unknown	
	GU:	Unknown	
	MSK:	Unknown	INT: Unknown

B. Baseline Simulator State and Physical Exam			
No Monitor Display	Monitor On, no data displayed	Monitor on Standard Display	
HR: 132/min	BP: 105/80	RR: 24/min	O_2SAT: 98% RA
Rhythm: sinus	T: 37.0°C	Glucose: 6mmol/L	GCS: 11 (3E 4V 4M)
General Status: agitated, confused, lashing out			
CNS:	GCS 11 (E3, V4, M4), PEARL, moves all 4 limbs		

© 2015 EMSIMCASES.COM
This work is licensed under a Creative Commons Attribution-ShareAlike 4.0 International License.

Penetrating Abdominal Trauma

HEENT:	No obvious head injuries, normal exam		
CVS:	S1S2, tachycardic, no murmurs		
RESP:	GAEB, no EBS, lungs clear		
ABDO:	Abdomen is soft, tender, no guarding or rigidity 1 inch long, deep laceration in the upper left quadrant IF they log roll to look at the back they will see 2 lacerations on the left, one is superficial and in the thorax (no air bubbling) and a deeper, more severe 1 inch wound on the left flank		
GU:	normal		
MSK:	Pulses present and moves all 4 limbs appropriately, but cool peripheries	SKIN:	Superficial ~1inch wounds on right forearm, right palm Deep penetrating left upper quadrant wound Deep penetrating wound to the left flank

© 2015 EMSIMCASES.COM
This work is licensed under a Creative Commons Attribution-ShareAlike 4.0 International License.

Penetrating Abdominal Trauma

Scenario States, Modifiers and Triggers			
Patient State	Patient Status	Learner Actions, Modifiers & Triggers to Move to Next State	

1. Baseline State
Rhythm: sinus
HR: 132/min
BP: 105/80
RR: 24/min
O_2SAT: 98%
T: 37.0 ^oC
	Patient is agitated and confused.
	Yelling out and lashing out
		Learner Actions
		- Identifies patient is in distress - Gives sedating medication to settle patient to allow for assessment and IV placement
		  o IM ketamine (5mg/kg IM)
		  o haloperidol (5mg IM) or
		  o midazolam (5mg IM)
		- Does complete primary and secondary survey and identifies serious abdominal and flank wound
		- Call for help (code trauma, surgery, ICU)
		- Abdominal exam is benign
		- Bedside POCUS – no free fluid in abdomen, but IVC appears slightly flattened
		- Orders O- blood and considers MTP
		- Identifies need for advanced imaging and recognizes seriousness of injury and prepares for intubation
		- Orders labs: CBC, CP7, coagulation, type and cross match, lactate, abdominal panel
			Modifiers
			Changes to patient condition based on learner action
			- Gives sedation to facilitate assessment and IV placement
			- Identifies flank wound and need for blood
			- Identifies need for advanced imaging and airway management
			- Calls for help early
			
			Triggers
			For progression to next state
			- No blood started, patient decompensates - proceed to stage 2
			- No sedation given – unable to assess and patient decompensates - proceed to stage 2
			- If sent to CT without intubation patient codes in scanner and END CASE
			- If patient intubated and stabilized can go to CT successfully. Learner needs to communicate with involved specialties – trauma, ICU, surgery, radiology – stage 4

2. Decompensation Rhythm: sinus HR: 130/min BP: 90/65 RR: 30/min O_2SAT: 98% T: 37^oC GCS: 8, E2V2M4	Patient decompensates	Learner Actions - Acknowledges patient's change - Repeat POCUS – free fluid in Morrison's Pouch - repeat abdominal exam – now has rigidity, guarding, rebound tenderness - Prepares for intubation with ketamine (0.5-1mg/kg IV) and rocuronium	Modifiers - If patient stabilized and trauma code called, trauma lead arrives and takes over as patient is too unstable to go to CT Triggers - If decompensated state not recognized proceed to stage 3

© 2015 EMSIMCASES.COM
This work is licensed under a Creative Commons Attribution-ShareAlike 4.0 International License.

		(1.5mg/kg IV) given shock index – IV is placed - Has push dose phenylephrine available or considers vasopressors on hand - Stabilizes patient with blood and considers massive transfusion protocol - Call code trauma	- If patient stabilized – trauma lead takes over and END CASE
3. PEA Arrest Rhythm: sinus HR: 130/min BP: 0/0 RR: 0/min O_2SAT: 92% and falling T: 37°C	PEA arrest	Learner Actions - Proceed through ACLS algorithm	Modifiers - Gives blood and intubates – gets ROSC after 2 rounds of CPR Triggers - Does not treat underlying cause and patient dies, complete 2 rounds of CPR pathway – END CASE - Treats underlying illness and patient stabilizes, call code Trauma and END CASE
4. Definitive Treatment Rhythm: sinus HR: 110/min BP: 100/70 RR: Vented/min O_2SAT: 100% T: 37°C		Learner Actions - Patient to CT - General surgery, trauma, ICU, radiology called	Modifiers - END CASE Triggers

© 2015 EMSIMCASES.COM
This work is licensed under a Creative Commons Attribution-ShareAlike 4.0 International License.

© 2015 EMSIMCASES.COM
This work is licensed under a Creative Commons Attribution-ShareAlike 4.0 International License.

Laboratory Results						
Na:	K:	Cl:	HCO_3:	BUN:	Cr:	Glu:
Ca:	Mg:	PO_4:	Albumin:			
VBG	pH:	PCO_2:	PO_2:	HCO_3:	Lactate:	
WBC:	Hg:	Hct:	Plt:			

Images (ECGs, CXRs, etc.)

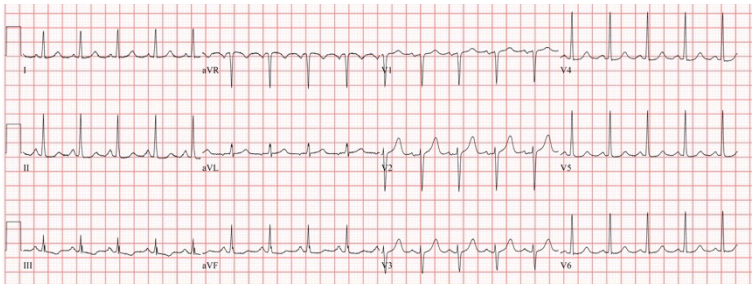

https://en.ecgpedia.org/images/f/f8/Sinustachycardia.jpg Accessed Nov 7th, 2022

Levis, Joel. Figure *54.1* *Stab wounds to the abdomen (panel A) of a 16-year-old male.* Clinical emergency medicine casebook. 2021. Color atlas of emergency trauma. Levis, Joel. Cambridge Univeristy Press. 2009. Accessed Nov 7th, 2022

© 2015 EMSIMCASES.COM
This work is licensed under a Creative Commons Attribution-ShareAlike 4.0 International License.

Penetrating Abdominal Trauma

Levis, Joel. Figure *54.1* *Stab wounds to the left flank (panel B) of a 16-year-old male.* Clinical emergency medicine casebook. 2021. Color atlas of emergency trauma. Levis, Joel. Cambridge Univeristy Press. 2020. Accessed Nov 7th, 2022

Ultrasound Video Files (if applicable)

IVC Ultrasound:

https://www.youtube.com/watch?v=8wRpTJQ0634

Accessed Nov 15th, 2022

Abdominal Ultrasound #1 – negative for free fluid

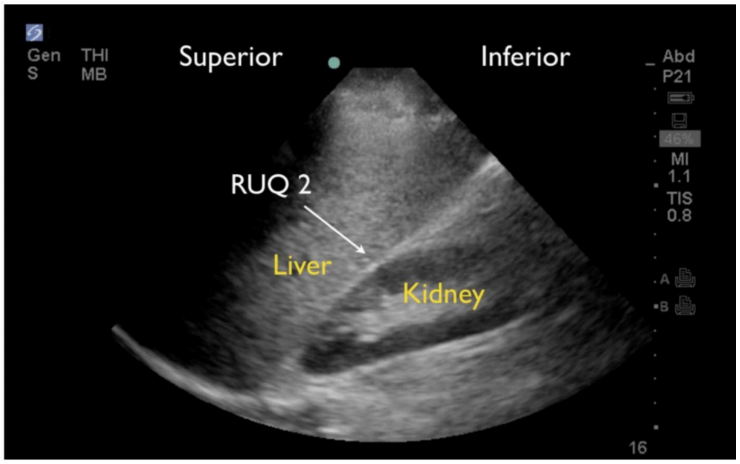

https://www.researchgate.net/figure/Normal-right-upper-quadrant-FAST-view-showing-no-free-fluid-in-

© 2015 EMSIMCASES.COM
This work is licensed under a Creative Commons Attribution-ShareAlike 4.0 International License.

Penetrating Abdominal Trauma

	Morisons-pouch-RUQ2_fig3_313415975. Accessed Nov 15th, 2022.
	Abdominal Ultrasound #2 – free fluid 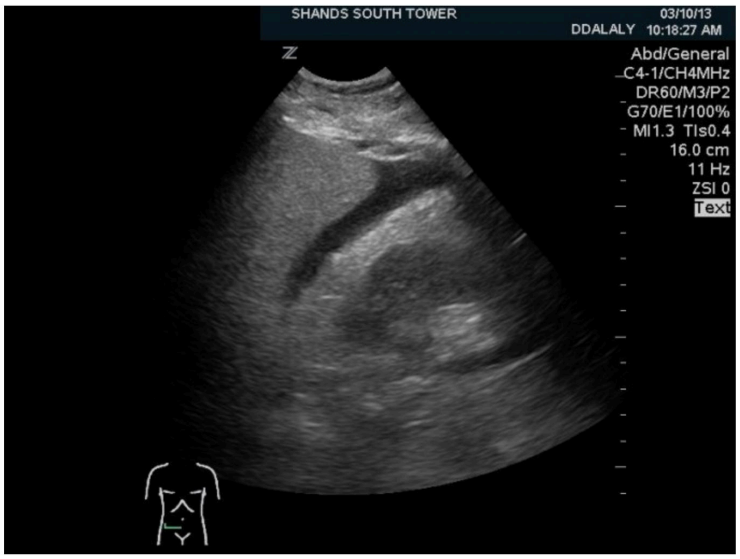 https://anest.ufl.edu/clinical-divisions/critical-care-medicine/critical-care-ultrasonography/ultrasound-training-videos-abdomen/. Accessed Nov 15th, 2022.

© 2015 EMSIMCASES.COM
This work is licensed under a Creative Commons Attribution-ShareAlike 4.0 International License.

Penetrating Abdominal Trauma

Section VIII: Debriefing Guide

General Debriefing Plan			
Individual	Group	With Video	Without Video

Objectives	
Educational Goal:	
CRM Objectives:	
Medical Objectives:	

Sample Questions for Debriefing

1. Should you intubate this patient before imaging?
2. What are the signs that this patient is in shock?
    a. Discuss Shock Index
3. What is included in the primary and secondary survey?
4. What are some causes of agitation?
5. Discuss the importance of serial abdominal POCUS and physical exams in patients with high index of suspicion for severe penetrating abdominal trauma

Key Moments

© 2015 EMSIMCASES.COM
This work is licensed under a Creative Commons Attribution-ShareAlike 4.0 International License.